

The management of heavily exudating wounds with super absorbent dressings

Sue Johnson RN MA EFNP Suppl. Pres CNS Wound Care & Kathy Leak RN BA (Hons) EFNP Suppl. Pres. Sister Wound Care Doncaster and Bassetlaw Hospitals NHS Trust

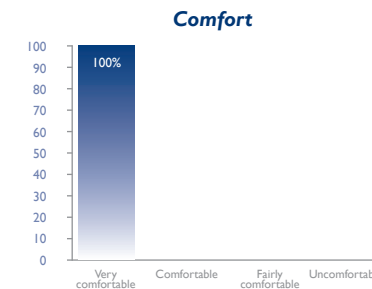
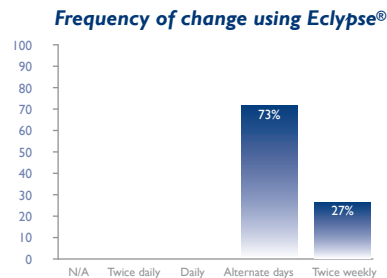
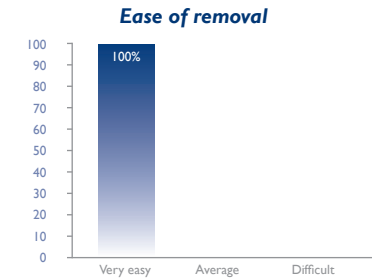
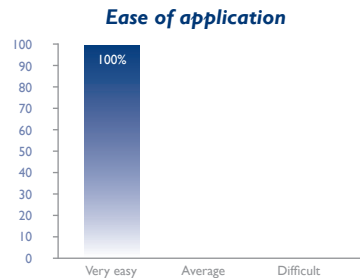
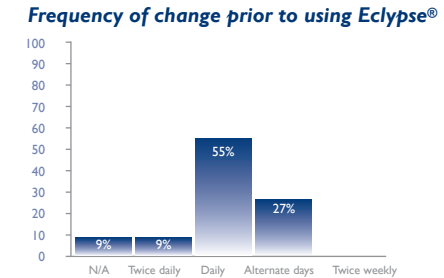
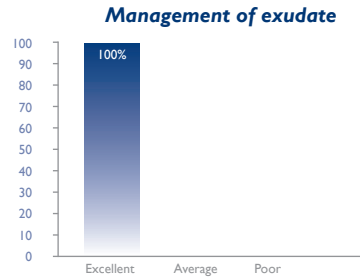
Introduction

The management of exudate is a commonly cited clinical problem. All community based nurses have had at one time or another a patient, with limited mobility, with large oedematous legs that leak all over the floor. With an increasingly aged population and improved technology and operative expertise we are encountering more patients with large exudating wounds. When contained within the wound space, exudate performs a valuable role in wound healing. Excessive wound exudate or other bodily fluids, such as urine or sweat, can cause skin maceration to occur around a wound, which may delay healing and lead to other complications.

To ensure an optimal healing environment correct dressing selection and use is paramount to ensure a positive healing outcome. A new highly adsorbent pad (Eclipse®) is now available. The dressing comprises of a rapidly wicking polyester and viscose spun woven face combined with a high capacity sheet of absorbent crystals and mechanically bonded cellulose pad. The backing is a polyester fluid repellent film designed to prevent strike through.

The aim of this study was to evaluate the use of the new super absorbent dressing in management of heavily exudating wounds including dehisced abdominal wounds, fungating wounds and heavily exuding leg ulcers.

Of the twelve cases presented the results are as follows:



Results

The dressing pad performed better than the previously used dressing pad, reducing dressing changes by 50%. There was a reduction in skin damage due to the unique method of securing the dressing and a reduction in pain at dressing change again due to the unique method of securing the dressing.

Conclusion

The super absorbent dressing pad enabled the management of high levels of exudate and patients' quality of life was substantially improved. There was a reduction in the number of hospital bed days as the exudate were managed better and therefore the patients was able to be discharged earlier. The patients quality of life was improved as the fear of accidental leakage from their wound was removed. There was a reduction in skin stripping due to the unique securing method negating the need for tape to secure the dressing pad in place.

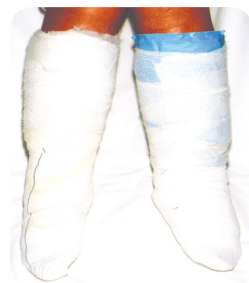Case Study 1

58 year old lady with Rheumatoid Arthritis, has been on steroids since 1994. She has been troubled with recurrent ankle oedema and Osteoporosis since 2000. Her past history also includes Angio-oedema and more recently she has been troubled by recurrent cellulitis with heavily exuding legs. The dressings being used needed frequent changes due to strike through, this usually occurring within one hour of the dressing being changed. As both legs were affected it was decided to apply traditional treatment to the right leg, and the Eclipse® pads to the left leg.

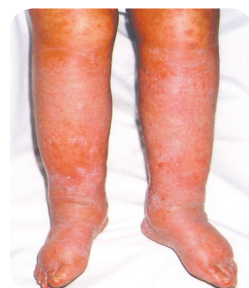Right Leg: This needed changing four times within the twenty four hour period, while the patient was on bed rest, requiring a lot of nursing time and equipment plus discomfort to the patient as her legs were becoming macerated from the exudate.

Left Leg: After 24 hours the results can be seen. Upon removal there was no evidence of maceration on the left leg

as the dressing had wicked away the exudate preventing skin maceration.



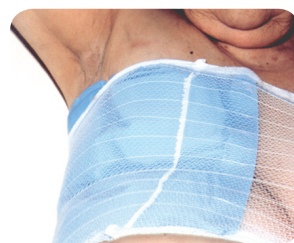
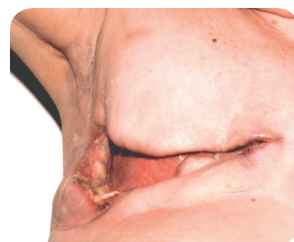Right leg: Viscopaste (Smith and Nephew) applied toe to knee. Mesorb dressing pad (8 mesorb pads were needed) softban and a retention bandage.



Left leg: Viscopaste was again applied toe to knee Eclipse® on top (4 pads were needed). Retention bandage to secure in place.

Case Study 2

Mrs H is a 76 year old lady who underwent a left mastectomy



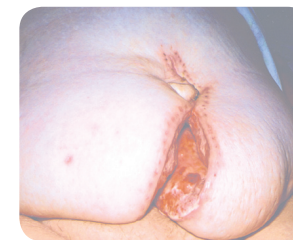and axillary clearance in December of last year. On the 6th January 2004 the wound dehised and the wound was dressed according to the Breast clinic protocols. On the 13th January 2004 Mrs H was referred to the Wound Care team. On presentation the wound was completely dehised with maceration of the skin edges and surrounding skin with some skin stripping, from the adhesive tape used, due to the wound requiring dressing two

– three times a day. There was copious amounts of exudate, the wound bed was sloughy with some necrosis of the skin

edges. The wound was dressed with Aquacel AG and the Eclipse® dressing as the secondary dressing. Within a week the skin maceration had resolved, the wound bed showed 100% granulation tissue and dressing changes had reduced to daily. No strike through occurring between dressing changes. As the dressings were now secured with a netalast vest the skin stripping had also resolved. At the present time Mrs H's wound has not completely healed but is now being managed with Aquacel and Versiva requiring changing two – three times a week.

Case Study 3

Mrs M is a 67 year old lady who underwent a repair of incisional hernia in August of last year. Her past medical history includes Arthritis, Asthma and 3 previous caesarean sections. She has suffered with a large umbilical and incisional hernia for 2 years resulting in several inpatient stays for problems related to this. 10 days post op Mrs M's wound



was oozing haemoserous fluid. The following day alternate sutures were removed resulting in dehiscence of the wound. The remaining sutures were removed. The wound cavity was filled with Sorbsan and a Mesorb dressing pad applied as a secondary dressing. This required changing twice a day but strike through did occur prior to all dressing changes. Following referral to the Wound Care team 3 days later the dressing regime was changed to Sorbsan and Eclipse® as the secondary dressing. Dressing changes reduced immediately to alternate days with no strike through occurring between dressing changes. This resulted in Mrs M being discharged home in the care of the District Nurse 11 days later. The wound was completely healed 6 weeks later.